Loay Hatem Ali et al /J. Pharm. Sci. & Res. Vol. 9(10), 2017, 1698-1700

ISSN:0975-1459
Journal of Pharmaceutical Sciences and Research
www.jpsr.pharmainfo.in

Histological Alterations in Leukocytes of Patients suffering Leukemia by Scanning Electron Microscope

Loay Hatem Ali, Haitham L. Abdulhadi
Biology Department, College of Education for Pure Sciences,
University of Anbar, Iraq

Abstract

Aim of study: Leukemia is known as cancer of white blood cells. This research was performed to enlighten the ultra-structural changes that occur in leukocytes of the patients who are diagnosed of leukemia in Basra, Iraq.

Materials and Methods: Blood was withdrawn from 15 leukemic children who reported to Basra Hospital in the years 2012-2015. The samples taken were examined by a transmission electron microscopy.

Results: The result shows that there were immature leukocytes present with a varied structure as compared to their normal structure. Adherence phenomenon was observed in this group of leukocytes.

Conclusions: There was a shift in the rates of leukemia seen in young children in the past couple of years that suggested a strong link between low level radiation (LLR) exposure and leukemia.

Key word: Leukemia, Leukocyte, Ultra structural

INTRODUCTION

Basra is known to be the second largest city of Iraq. Being the second largest city, faces a large chunk of air pollution. It has faced such issues in the past including depleted uranium (DU) because of the state of warfare in Iraq. Many studies have claimed that there was a rise in the rate of cancer in the city of Basra [1]. It faces a lot of environmental issues that are of both intermediate as well as severe in nature and are seen to be directly associated with the military activities [2]. DU decays after it has released alpha particles that in turn affect the internal body cells (more prone to the ionizing effect of alpha rays) when a person ingests or inhales DU. Other cancers that can develop are leukemia, lung cancer [3, 4]. Even after this, many researches confirmed the fact that the use of DU has caused an increase in incidence of malignant diseases in the city of Basra [5].

There is no evidence that is related to its effects if it is depicted by the structure of leukocytes that have been withdrawn from the blood samples. This research was performed to emphasize on these effects on the leukocytes.

MATERIALS AND METHODS

For checking these samples of blood, transmission electron microscopy study was performed in which 15 children (8 to 10 years of age) admitted in Basra Hospital in the year 2012, having leukemia were taken to be the part of research. Samples withdrawn were centrifuged at 1000 rpm for about 8 to 10 minutes according to the procedure [6]. Buffy coat is then aspirated and the cells are bathed in 2.5% phosphate buffered glutaraldehyde at pH 7.4, fixed for 3h at 45 C^o. The pellet samples were washed twice in a buffered saline solution, post fixed with phosphate buffered 1% osmium tetroxide, is dehydrated in graded alcohol as well as propylene oxide. After the process of infiltration occurs by the help of an araldite propylene oxide mixture for 24 h, the specimens are fixated in araldite according to the directions of the procedure [7]. Silver-gold interference sections were taken on a Jung Ultra microtome, it is placed on a mesh grid that is coated with uranyl acetate as well as lead citrate, and is examined using the Philips 210 transmission microscope in Al-Nahreen University.

RESULTS

Transmission electron microscopic examination shows various changes in the blood of leukemia patients and is represented by the followings:

1. Agglomeration of leukocytes was seen (figure 1, 2, 3, 4)
2. Immature leukocytes cells (also known as blast cells) were identified because of large cells with a high nuclear to cytoplasmic ratio. There was nuclear enlargement and a varied shape, which is from oval to irregular in shape the chromatin, was finely granular. A narrow circumference of condensed chromatin accentuated the nuclear outline, finely granular chromatin, prominent nucleolus with increased electron density chromatin, and relatively few but variable numbers of cytoplasmic organelles like ribosomes, mitochondria, endoplasmic reticulum and Golgi complex (fig 2).
3. Cells were round in shape, had various irregular surface projections or microvilli with increment of electron density of mitochondria and increment of nucleolus number (fig4).
4. Progressive nuclear indentation and segmentation, and the appearance of cytoplasmic granules and glycogen aggregates were seen within the myeloid cells (fig 3).
5. Immature leukocyte was molded into phagocytic cells since RBC was found in their cytoplasm (fig 5).
6. Formation of chromatin bridges between the two types of leukocytes besides lipid droplets and cytoplasmic vacuoles present (fig 8).
7. Long cisterns of dilated endoplasmic reticulum were appreciated in some cells (most of the cells), a few

small to medium-sized dense granules were seen in most cells. Also, apoptotic leukocyte was found (fig 6).

8. Elytroid cells had ferritin aggregates present within the cytoplasm leading to increased cytoplasmic density that correlates with hemoglobin synthesis (fig 9).

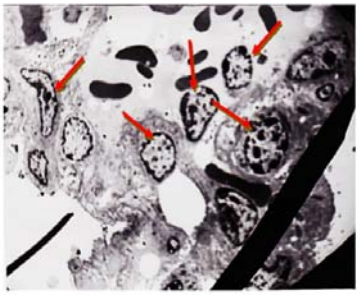

Figure 1: General appearance of immature agglomerate leukocytes ( ) seen in the blood of patients effected by leukemia. Lead citrate and Uranyl acetate (2600x).

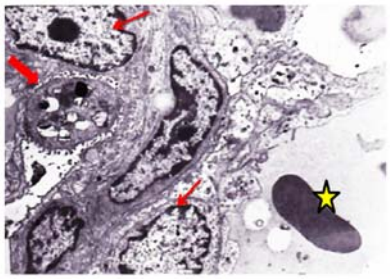

Figure 2: Immature agglomerate leukocyte in blood of patients affected by leukemia. Large sized nucleus is seen within dented nuclear envelop ( ), platelets ( ), R.B.C ( ).Uranyl acetate and lead citrate, (4600x)

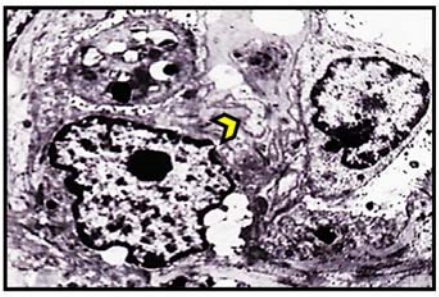

Figure 3: Immature agglomerate leukocyte is seen in blood of patients affected by leukemia. Note the increase in nuclear cytoplasmic ratio, cytoplasm granule ( ), glycogen granule ( ), microvilli projection ( ), dilated endoplasmic reticulum ( ).Uranyl acetate and lead citrate, (5800x)

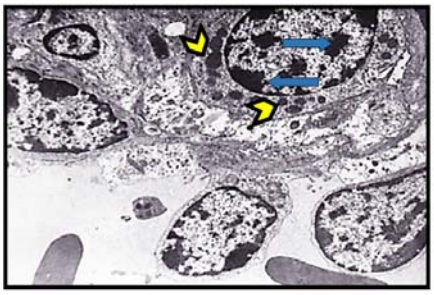

Figure 4: Immature agglomerate leukocyte is seen in blood of patients having leukemia. Mitochondria has high electron density ( ), increment in nucleolus number ( ). Uranyl acetate and lead citrate, (4600x)

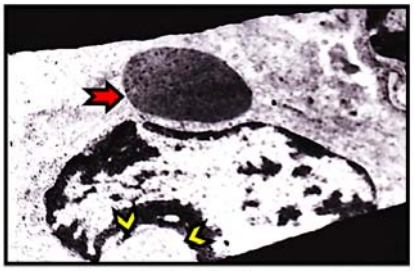

Figure 5: immature leukocytes in blood of patients are seen having leukemia disease. Leukocytes are also transformed in phagocytic cells. RBCs having ferritin ppt. ( ), irregular nucleus ( ) .Uranyl acetate and lead citrate, (7900x)

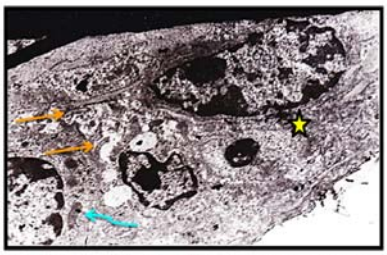

Figure 6: Immature agglomerate leukocyte in blood of patients having leukemia. Apoptotic leukocyte ( ), dilated cisternae of endoplasmic reticulum ( ), mitochondria with high electron density ( ), Uranyl acetate and lead citrate, (5800x)

Figure 7: Immature agglomerate leukocyte in blood of patients having leukemia disease. Note the granular cytoplasm ( ).Uranyl acetate and lead citrate, (7900 x)

Figure 8: Immature agglomerate leukocyte in blood of patients having leukemia. Chromatin bridges are formed between two different nuclei type ( ), lipid droplet ( ), vacuole ( ), Uranyl acetate and lead citrate, (4600x)



Figure 9: Elytroid cells with cytoplasmic ferritin aggregates in patients having leukemia disease,), Uranyl acetate and lead citrate, (2600x)

DISCUSSION:

Leukemia is also known as cancer of white blood cells. It starts to progress from the bone marrow and extends to blood as well as other organs. There are many kinds of leukemia [8, 9]. These leukemia's are classified in two groups. One is on the basis of disease progression: (acute and chronic leukemia) while the other is by the type of blood cell involved (lymphocytic and myeloid leukemia being the most common) [10]. Acute myeloid leukemia has most of the leukocytes that are found to be immature and are unable to function normally [11, 12]. These changes were thought to be because of the atmosphere in Iraq and the constant population exposure to DU weaponry or its contaminating remains. It is also widely known that a major chunk of the Iraqi population has been exposed to a greater dose of radioactivity as compared to the normal population of the world. Because of this there a much larger population exposure to radiation that cause a disease, these effected population were registered in 1995. The low level radiation has also resulted in diseases like congenital malformations, congenital heart diseases, malignancies, chromosomal aberration and various other malformations. The women amongst the exposed population had experienced sterility [13].

The rise in leukemia has been reported in younger children in the past couple of years and it's greatly linked to the geographical areas where contamination has taken place. Low level radiation (LLR) and the damage caused by it are seen to be directly related. DU decays by releasing alpha radiations that are unable to penetrate the outer layers of skin but have the tendency to go deeper in the internal layers of the body (which are more susceptible to the ionizing effects of alpha radiation) [14, 15]. Keeping this in mind, many researches established the fact that because of the use of DU in the year 1991 and 2003, there was a marked increase in the cased reporting malignant diseases [5, 16].

This paper emphasizes on the fact that adhesion phenomenon was seen in Leukemic cells that are responsible for making extracellular matrix (ECM) by synthesizing proteoglycans and its components [17]. Along with that, there are stromal cells that have the ability to produce fibronectin, laminin that are responsible for the production of hematopoietic cytokines that promote the interaction occurring in between hematopoietic and stromal cells by the help of cell adhesion molecules. It was seen that in addition to hematopoietic cytokines, adhesion molecules also cause signal transduction in hematopoietic precursors and thus cause cell proliferation that goes beyond brokering hematopoietic cell contact and forms adhesion to stromal cells and ECM elements [6]. It can assumed that:

1. The American administration still says that the biological and chemical agents of hydrocarbon smoke of oil field fires in southern Iraq are the reasons and not the exposure to the DU. this was false and misleading information.
2. It is only fair to conclude that the environment in Iraq and its population have been exposed continuously to DU weaponry or its contaminating remains.
3. There was an increased rate of leukemia occurring in young children in the past years that suggests a very strong association between LLR exposure and leukemia.

REFERENCES

[1] Douabul AAZ, Al Maarofi SS, Al-Saad HT, Al-Hassen S. Gaseous pollutants in Basra city, Iraq. Air, Soil and Water Research 2013;6:15.

[2] Alborz A. Environmental characteristics and prevalence of birth defects among children in post-war Iraq: implications for policies on rebuilding the Iraqi education system. Medicine, Conflict and Survival 2013;29:26-44.

[3] Almuqdadi K, Al-Ansari N. Risks of the Military uses f Depleted Uranium on Humans and the Environment. Journal of Earth Sciences and Geotechnical Engineering 2013;3:163-203.

[4] Sherer MAS, Visconti PJ, Ritenour ER, Haynes K. Radiation Protection in Medical Radiography-E-Book: Elsevier Health Sciences; 2014.

[5] Fathi RA, Matti LY, Al-Salih HS, Godbold D. Environmental pollution by depleted uranium in Iraq with special reference to Mosul and possible effects on cancer and birth defect rates. Medicine, Conflict and Survival 2013;29:7-25.

[6] Yaqoub A, Ajeel N, Al-Wiswasy M. Incidence and pattern of malignant diseases (excluding leukemia) during 1990-1997. Proceeding of the conference on health and environmental consequences of DU used by US and British forces in the1991. p. 2-3.

[7] Yacoub A, Ajeel N, Al-Wiswasy M. Incidence and pattern of malignant diseases (excluding leukemia) during 1990-1997. The Medical journal of Basrah University 1999;17:35-41.

[8] Hayat MA. Principles and techniques of electron microscopy. Biological applications: Edward Arnold.; 1981.

[9] Murphy K, Weaver C. Janeway's immunobiology: Garland Science; 2016.

[10] Arber DA, Orazi A, Hasserjian R, Thiele J, Borowitz MJ, Le Beau MM, et al. The 2016 revision to the World Health Organization (WHO) classification of myeloid neoplasms and acute leukemia. Blood 2016:blood-2016-03-643544.

[11] Durakovic A. Medical effects of internal contamination with actinides: further controversy on depleted uranium and radioactive warfare. Environmental health and preventive medicine 2016;21:111-7.

[12] Miller AC, Bonait-Pellie C, Merlot RF, Michel J, Stewart M, Lison PD. Leukemic transformation of hematopoietic cells in mice internally exposed to depleted uranium. Molecular and cellular biochemistry 2005;279:97-104.

[13] Apperley J. CML in pregnancy and childhood. Best Practice & Research Clinical Haematology 2009;22:455-74.

[14] Joiner MC, Van der Kogel A. Basic clinical radiobiology: CRC press; 2016.

[15] Lothstein K, Fisher B, Li Y, Seif A, Harris T, Torp K, et al. Zoonotic infections in pediatric patients with acute leukemia. Pediatric blood & cancer 2013;60.

[16] Al-Azzawi SN. Depleted uranium radioactive contamination In Iraq: An overview. Global research 2006;1:4-8.

[17] Dyer O. WHO suppressed evidence on effects of depleted uranium, expert says. BMJ: British Medical Journal 2006;333:990.